Hyperdense Intracranial Vessels: Eliminating Observational & Interpretive Errors

L M Thornton, MD; L Lanier, MD; C L Sistrom, MD; D Rajderkar, MD; A Mancuso, MD; IM Schmalfuss, MD

University of Florida, Gainesville
Department of Radiology
RSNA Annual Meeting 2016

Call Readiness in Radiology Residency

- Trainee call readiness is important to patient safety
- Universal tools for call readiness evaluations
  - ✓ ACR In-Service Exam
  - ✓ Simulation Exam
- A computer based simulation (SIM) reflecting a typical emergency imaging shift was developed at our institution and administered to
  - ✓ 103 first (R1) & second (R2) year residents
  - ✓ From 9 radiology training programs in 2014

Call Readiness in Radiology Residency

- Comparison of ACR In-Service with SIM exam

ACR In-Service Exam	SIM Exam
Covers the entire spectrum of radiology	Presentation of dedicated emergency radiology cases only
Not specifically designed for assessing "independence"	Cases specifically chosen to assess patient's safety and resident's independence
Only key images are given minimizing observational error	Cases are presented as full DICOM image sets maximizing observational error
Lack of inclusion of normal studies	Inclusion of normal studies
Multiple choice questions assess passive knowledge	Free text responses access active knowledge
Inability to differentiate between observational & cognitive errors	Assessing observational versus cognitive errors

Case Presentation

Given history: 32 year old female with acute onset of weakness, diplopia and altered mental status. Possible seizure.

Non-contrasted, axial CT image of the SIM case shows markedly **hyperdense basilar artery** concerning for basilar artery occlusion. Hyperdense vessel(s) are often overlooked on CT especially when midline or symmetric in distribution.

Call Readiness in Radiology Residency

- SIM exam results:
  - 90% of residents failed to recognize the hyperdense basilar artery = observational error
  - Only 7% of residents raised the concern for basilar artery thrombosis
  - No significant difference in the performance between R1 and R2 residents
  - Independent of radiology program

Conclusion: Significant observational gaps exist in detection of hyperdense vasculature placing patients at risk for delay in diagnosis and appropriate treatment.

Purpose

- Purpose of this electronic exhibit is to close this observational gap by
  - Discussing key imaging features in identifying hyperdense vessels = observational error
  - Reviewing common pitfalls when making this diagnosis = cognitive error
  - Discussing appropriate action to take after making the correct diagnosis = patient safety issue

Pathophysiology of Hyperdense Vessels

- 40 HU = Hounsfield units for normal flowing blood
- Acute clot measures about 60-80 HU as it is red blood cell rich and poor in serum
- Chronic clot measures about 16-32 HU as it mainly consists of fibrin
- Other causes of elevated Hounsfield units within the vessel lumen
  - ✓ Calcium
  - ✓ Dilute contrast
  - ✓ Elevated hematocrit

Hyperdense Vasculature

- Arterial versus venous
- Single versus multiple hyperdense vessels
- Mimics

Single Hyperdense Arterial Vessel

Single Hyperdense Arterial Vessel

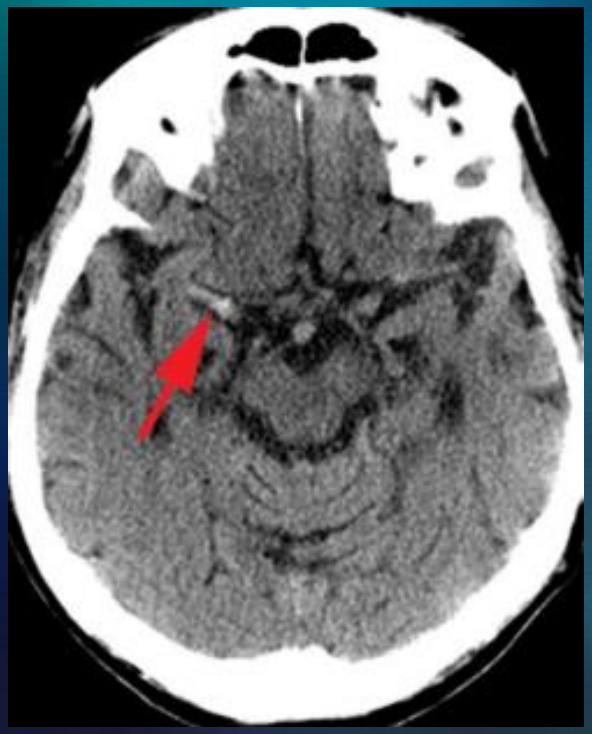

Non-contrasted, axial CT images of two different patients demonstrate **hyperdense proximal MCA** and **distal MCA** related to MCA artery occlusion. These hyperdense vessels are easier to depict than the SIM case as they are asymmetric in distribution.

Single Hyperdense Arterial Vessel

- Hyperdense MCA with CTA

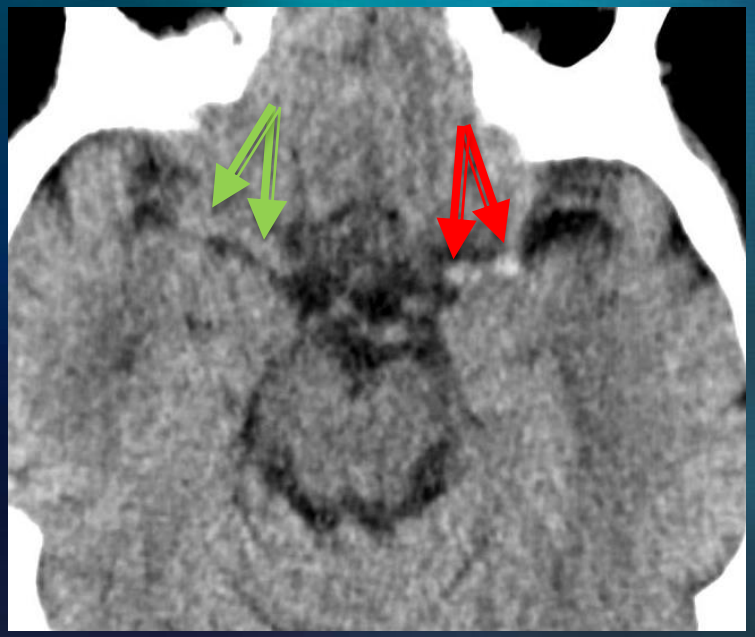

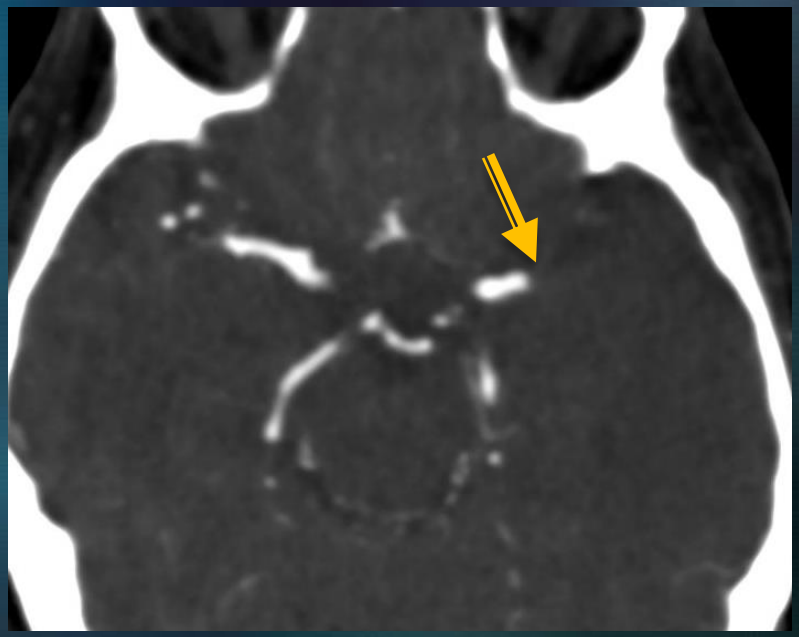

Notice the relative hyperdensity of the left **proximal M1** when compared to the **normal right M1** on this non-contrasted CT image. This can be seen with vessel occlusion even prior to loss of the grey-white differentiation or sulcal effacement. The CTA of the same patient shows a vessel cutoff confirming the diagnosis. This patient subsequently underwent thrombectomy.

Single Hyperdense Arterial Vessel

- Hyperdense MCA with MRI correlation

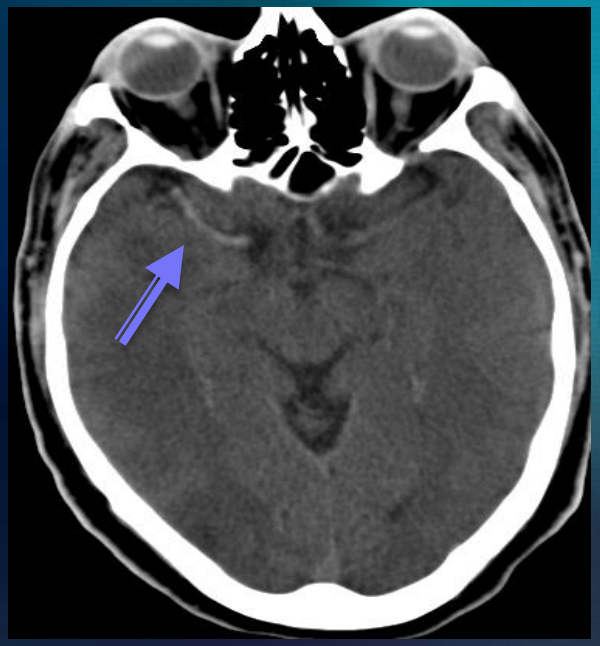

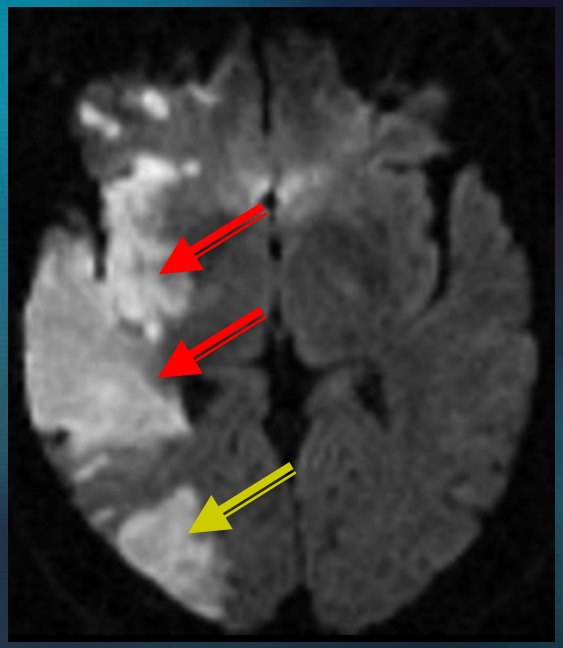

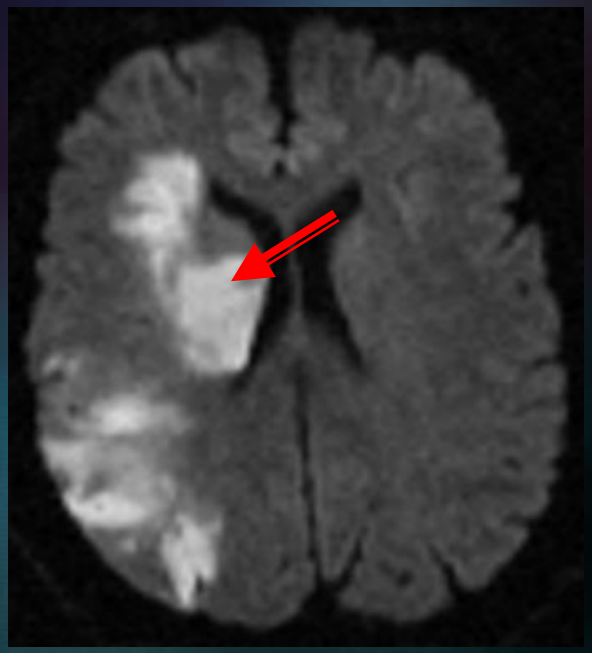

The non-contrasted, axial CT shows a homogeneously **hyperdense right MCA** suspicious for acute thrombus despite lack of secondary signs within the brain parenchyma. The subsequently performed MRI reveals **restricted diffusion in the right MCA territory** and **MCA/PCA watershed territory**. Advance to the next slide to see additional images

Single Hyperdense Arterial Vessel

- Hyperdense MCA with MRI correlation

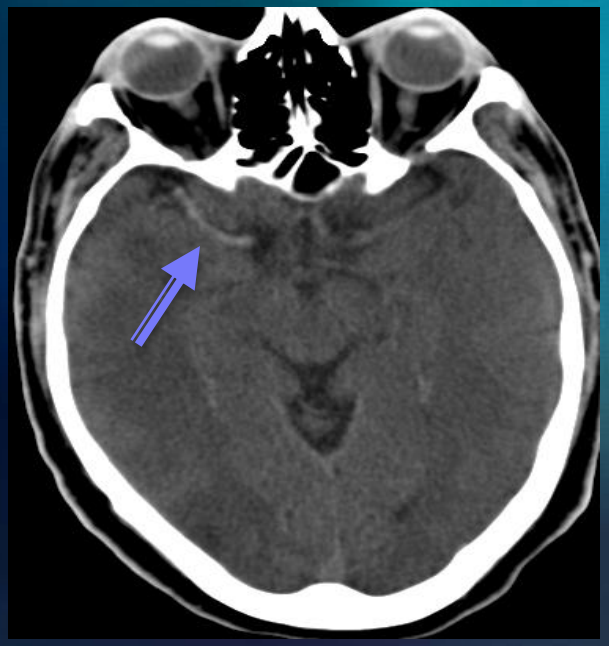

MRA of the same patient as on prior slide demonstrates **nonopacification of the right MCA** confirming the validity of the hyperdense vessel sign on CT. There is also **occlusion of the right ICA at its origin** on MRA of the neck.

Single Hyperdense Arterial Vessel

- Hyperdense basilar artery with CTA

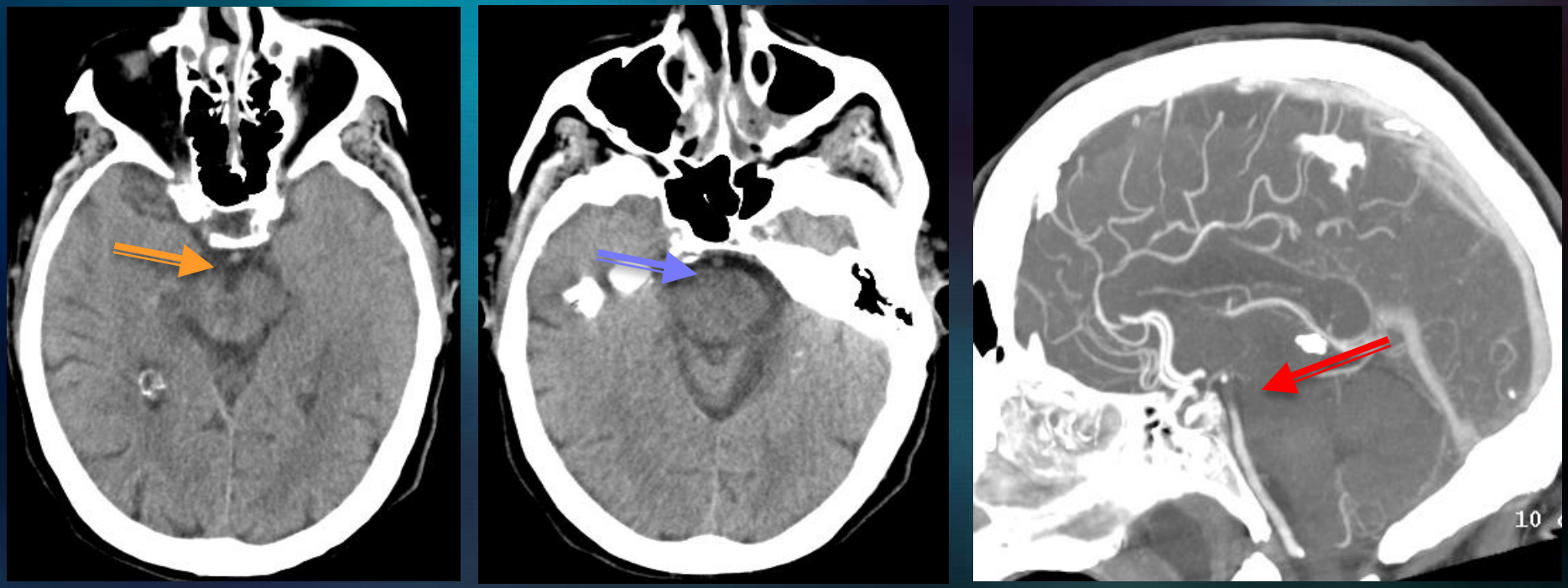

The non-contrasted, axial CT images show increased density of the **basilar artery at the midbrain level**. This is a subtle finding which becomes more conspicuous when compared to the basilar artery density **at the level of the pons**. The suspected **distal basilar artery occlusion** is confirmed on the sagittal CTA image.

Single Hyperdense Arterial Vessel

- Post traumatic vertebral Artery Dissection

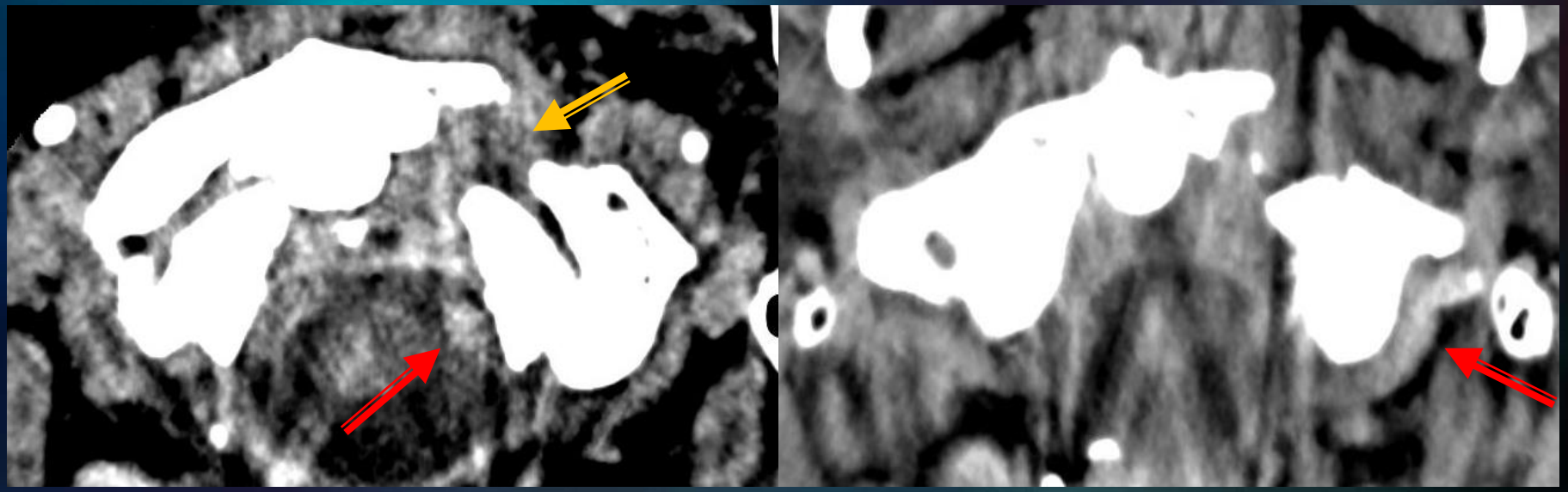

The non-contrasted cervical spine CT in soft tissue algorithm reveals subtle hyperdensity of the V3 & V4 segments of the **left vertebral artery**. This should be especially concerning if there are secondary findings of **cervical spine fracture**, seatbelt sign, or significant mechanism of injury as this can denote dissection or intramural hematoma. Advance to the next slide for additional images.

Single Hyperdense Arterial Vessel

- Vertebral Artery Dissection

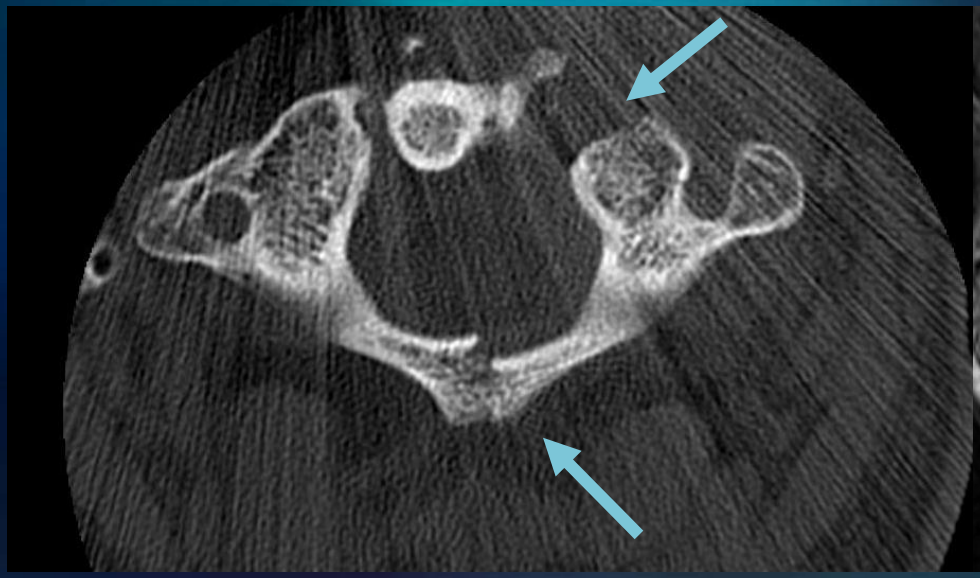

The non-contrasted cervical spine CT in bone algorithm better delineates the **fractures of the C1 ring** which were associated with a fracture of the dens (not pictured). The subsequently performed T2 images confirm abnormal flow in the left vertebral artery reflected as **hyperintense signal** in contrast to the **preserved normal flow void** in the right vertebral artery.

Single Hyperdense Arterial Vessel Mimics

Single Hyperdense Arterial Vessel Mimics

- Atherosclerosis - MCA

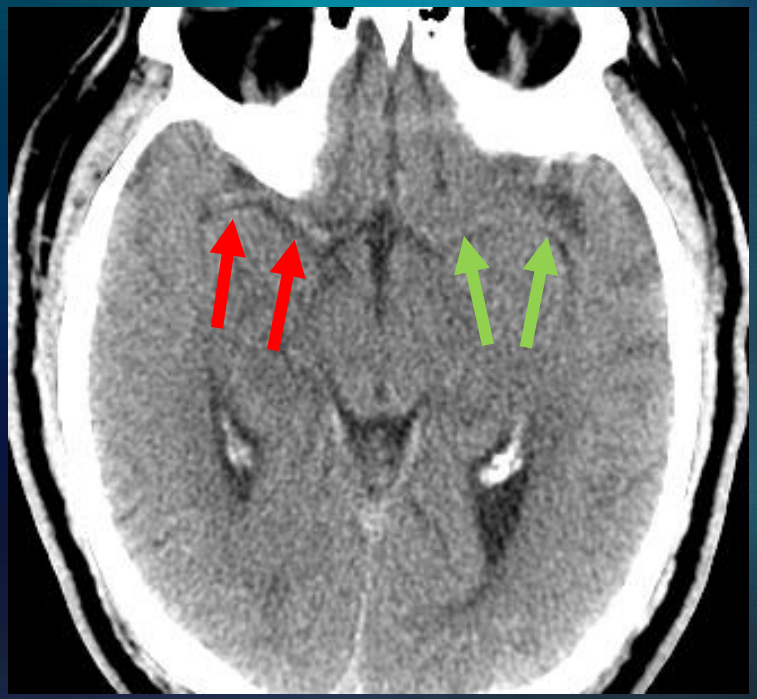

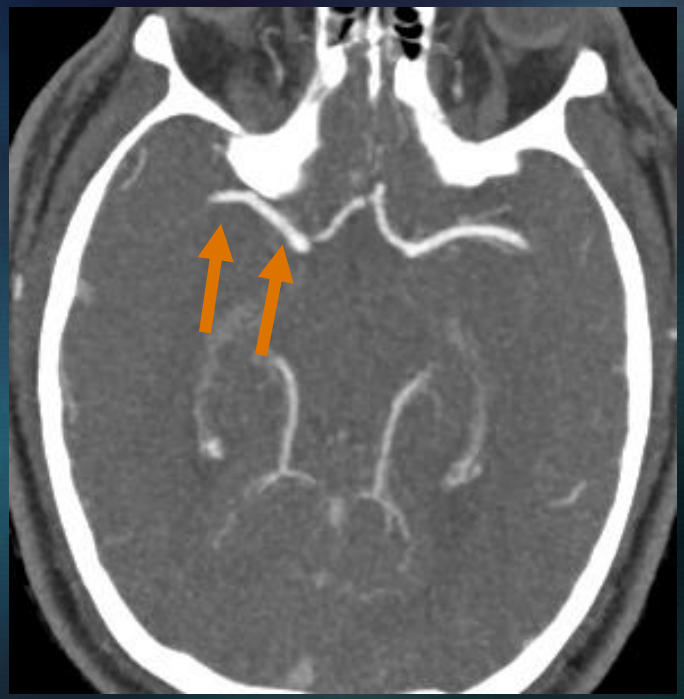

Non-contrasted CT reveals **hyperdense right MCA** when compared to the **normal left MCA**. Note that the hyperdensity is more patchy than confluent as in the previous case. This is more characteristic for calcium deposition due to atherosclerotic disease. The **patency of the right MCA** was confirmed with CTA.

Single Hyperdense Arterial Vessel Mimics

- Atherosclerosis of the Vertebral Artery

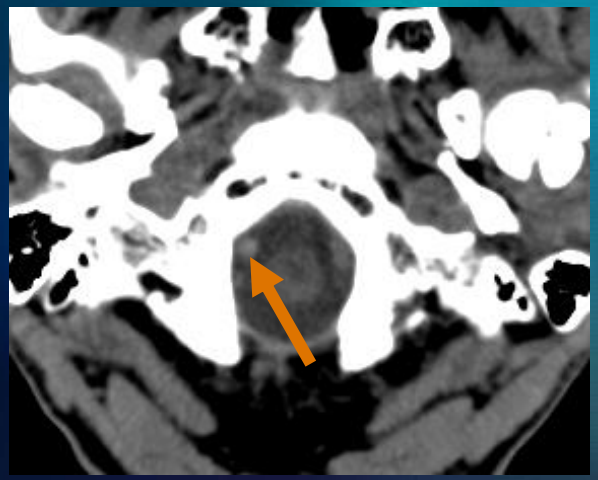

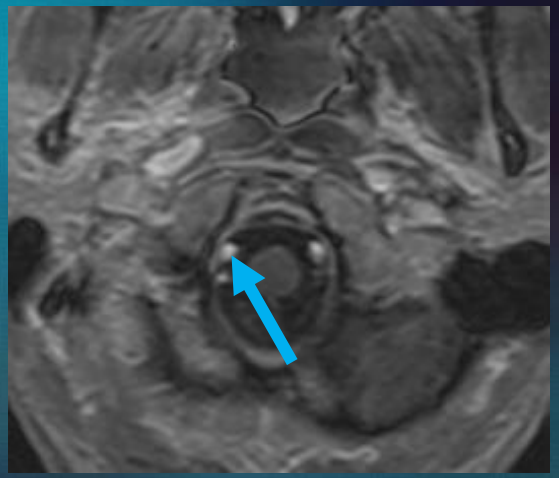

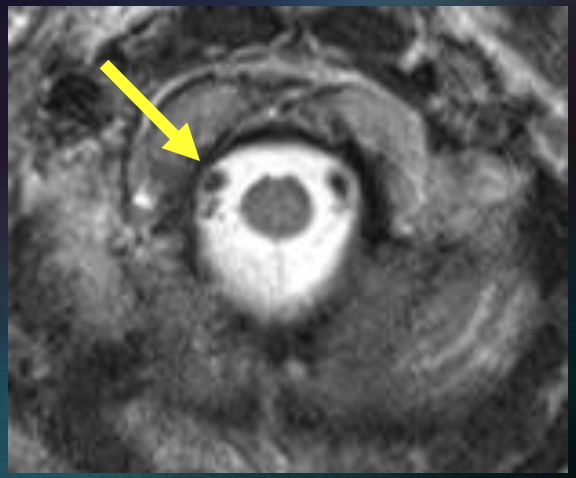

This non-contrasted CT image at the level of the foramen magnum was interpreted as **hyperdense** right vertebral artery due to thrombus or atherosclerosis. Subsequent MRI of the brain demonstrated **patency of the right vertebral artery** on post contrasted T1 without diffusion restriction. The T2 shows **irregularity within the vessel lumen** more consistent with atherosclerosis.

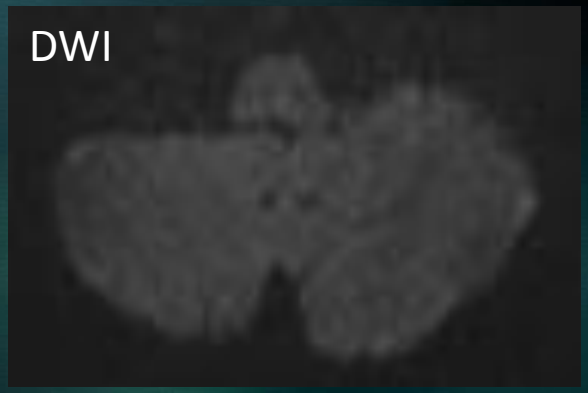

Single Hyperdense Arterial Vessel Mimics

- Atherosclerosis of the Basilar Artery

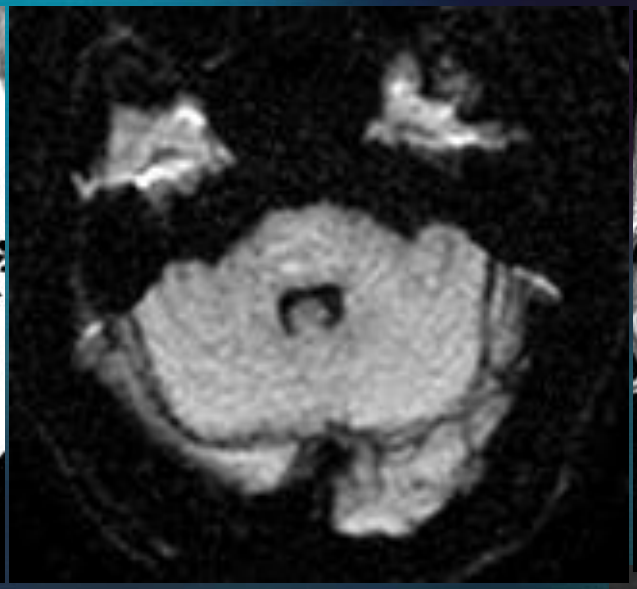

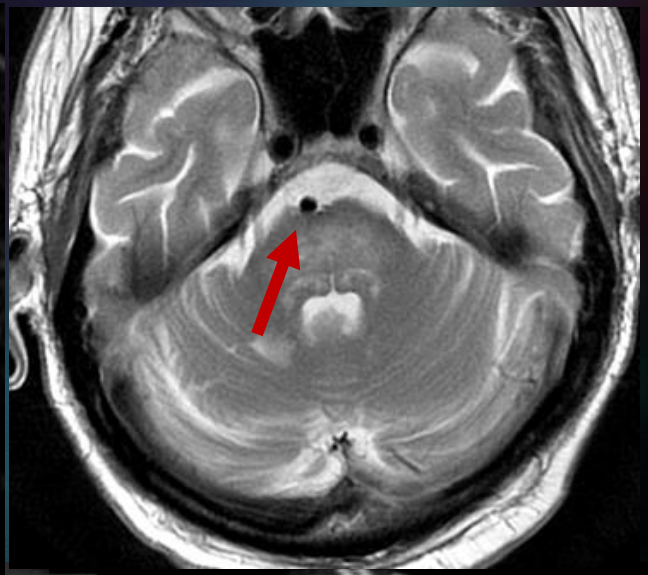

As in the SIM case, the **basilar artery** is **hyperdense** on this non-contrasted, axial CT image concerning for acute thrombus. However, the follow up MRI reveals no restricted diffusion and preservation of the **flow void** on T2 & **MRA MIP** images consistent with patent **basilar artery**.

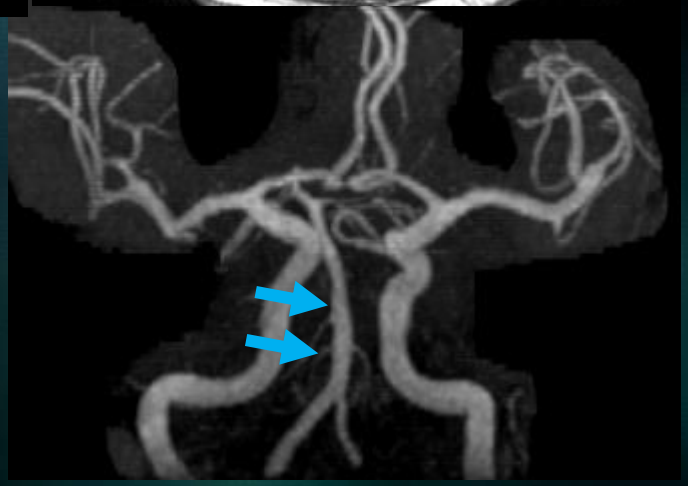

Single Hyperdense Venous Vessel

Single Hyperdense Venous Vessel

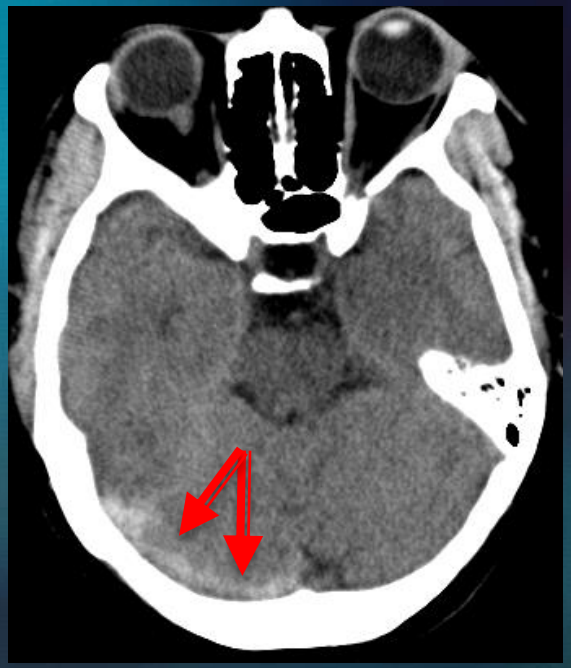

Non-contrasted, axial CT image reveals an **expanded and hyperdense right transverse sinus** consistent with transverse sinus thrombosis. The non-contrasted, axial CT image in a different patient shows a **more subtle hyperdensity of the right transverse sinus** that was confirmed to represent **thrombosis on the CTV**.

Single Hyperdense Venous Vessel

Non-contrasted, axial CT images show a **markedly hyperdense superior sagittal sinus**. This is harder to depict than the transverse sinus thrombosis on the prior slide due to the symmetric nature of the involvement. Sagittal T1 image confirms the **lack of flow void** consistent with posterior superior sagittal sinus thrombosis.

Multiple Hyperdense Venous Vessels

Multiple Hyperdense Venous Vessels

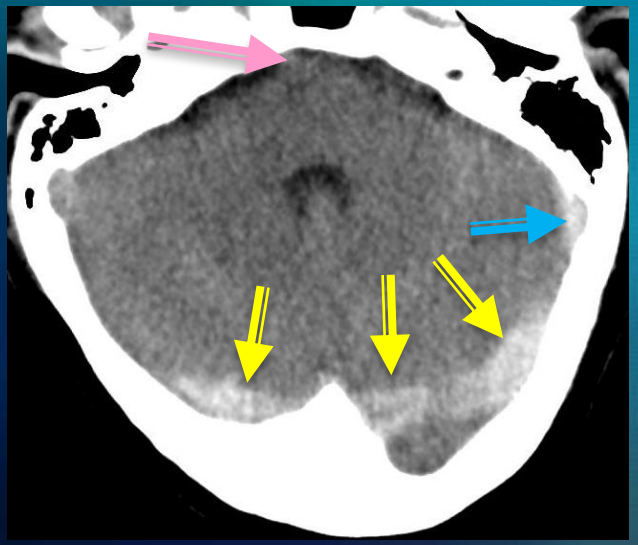

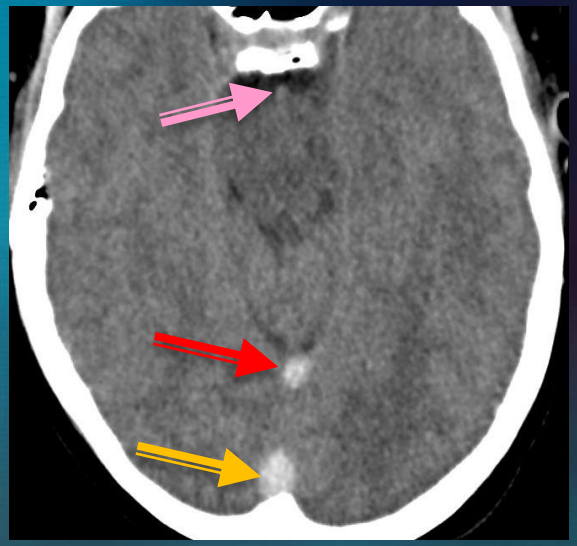

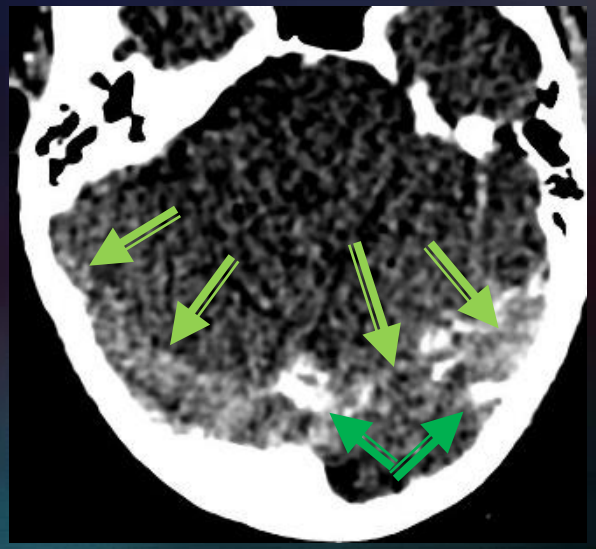

Note the **hyperdense appearance of the transverse sinuses bilaterally** with extension into the **left sigmoid sinus**, and **inferior** & **superior sagittal** sinuses. Due to the symmetric involvement, one could overlook this abnormality or consider it to be caused by a hyperosmotic state. However, note there is no corresponding increased density of the **basilar artery** to support the latter. On corresponding CTV the **transverse sinuses do not opacify** with contrast confirming the diagnosis of sinus thrombosis. Notice the **marked enhancement in the collateral dural veins**.

Multiple Hyperdense Venous Vessels

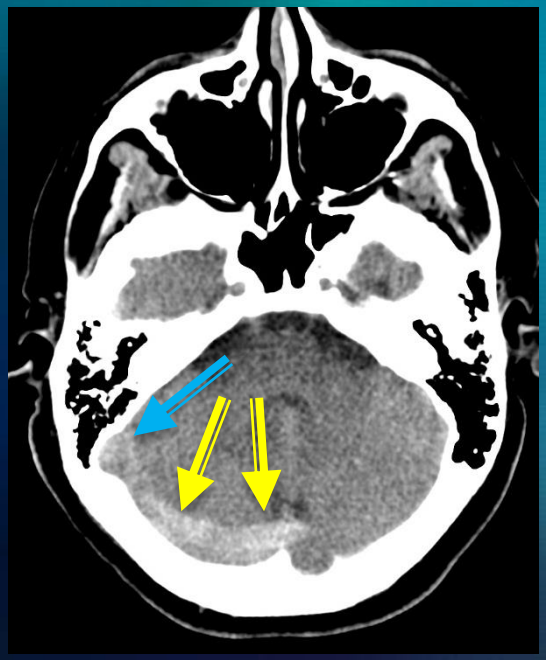

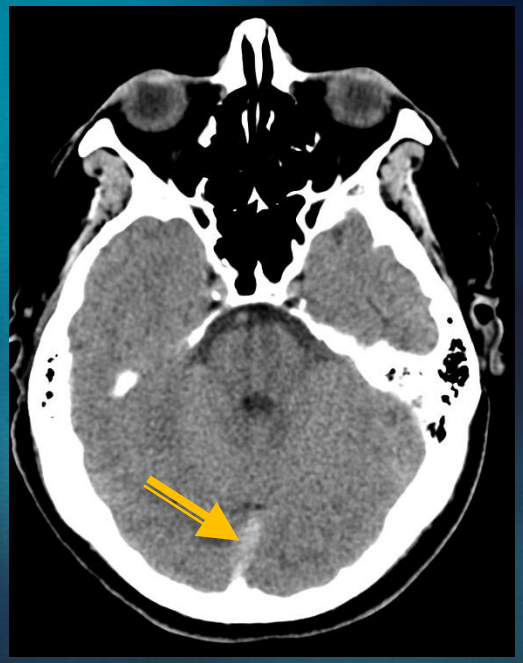

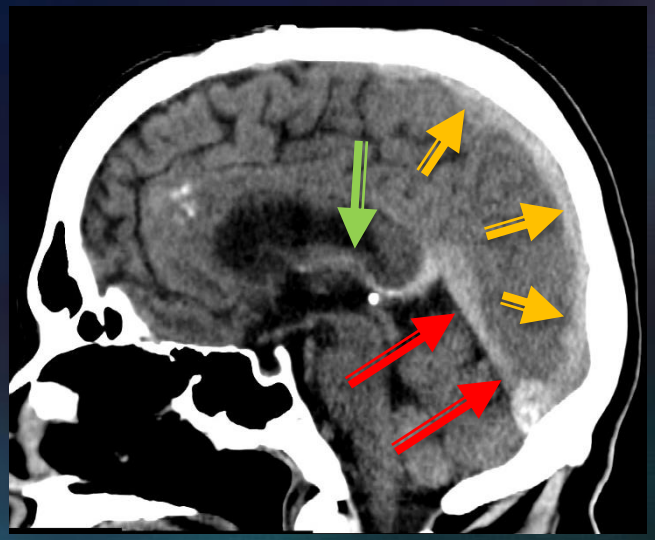

Extensive venous sinus thrombosis manifesting as distention and increased density of the **right transverse sinus, right sigmoid sinus**, **superior sagittal** sinus, **sinus rectus** & **internal cerebral vein**. The diagnosis was confirmed with MRV that shows patency of small, primarily cortical veins only .

MRV – AP view

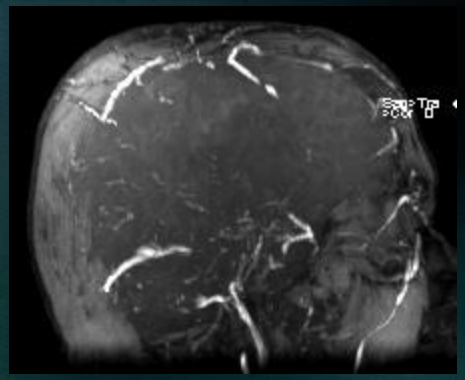

MRV – lateral view

Multiple Hyperdense Vessel Mimics

Multiple Hyperdense Vessel Mimic

- Polycythemia vera versus retained contrast

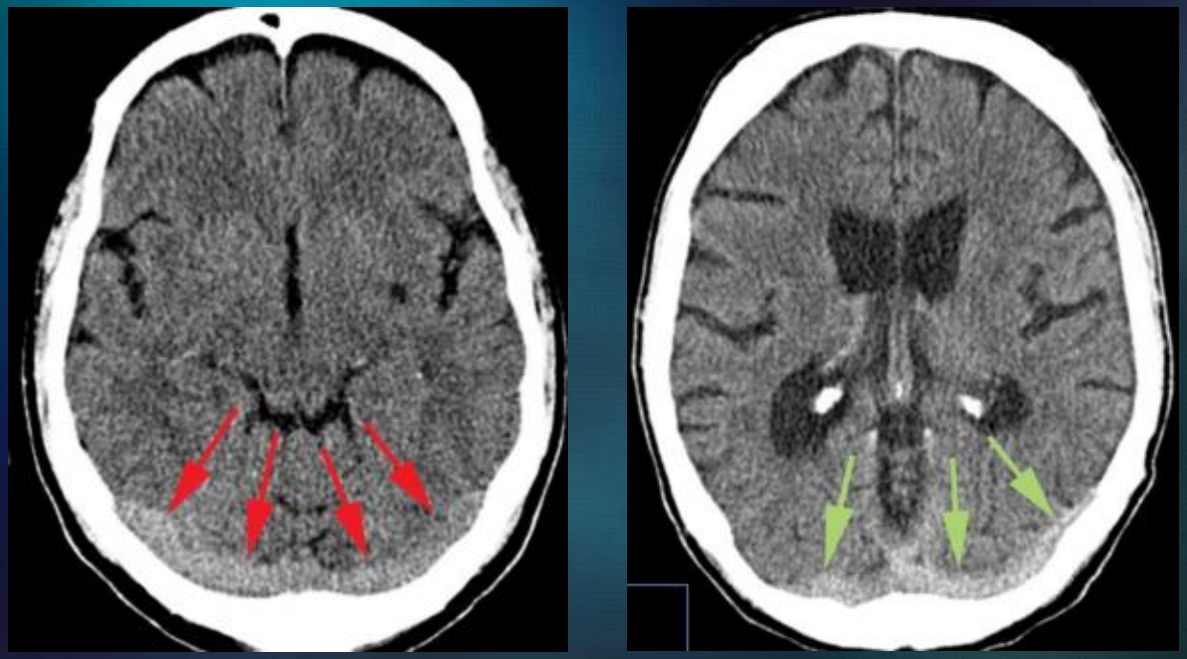

Non-contrasted, axial CT images of two different patients reveal bilateral hyperdense transverse sinuses. Such finding can be caused by bilateral transverse sinus thrombosis, elevated hematocrit due to dehydration or **polycythemia vera** and **retained contrast agent** in a chronic renal disease patient. Bilateral transverse sinus thrombosis usually manifests with significant neurological symptoms in contrast to the other patients that are typically neurologically intact.

Multiple Hyperdense Vessel Mimic

- Contrast Retention from Renal Disease

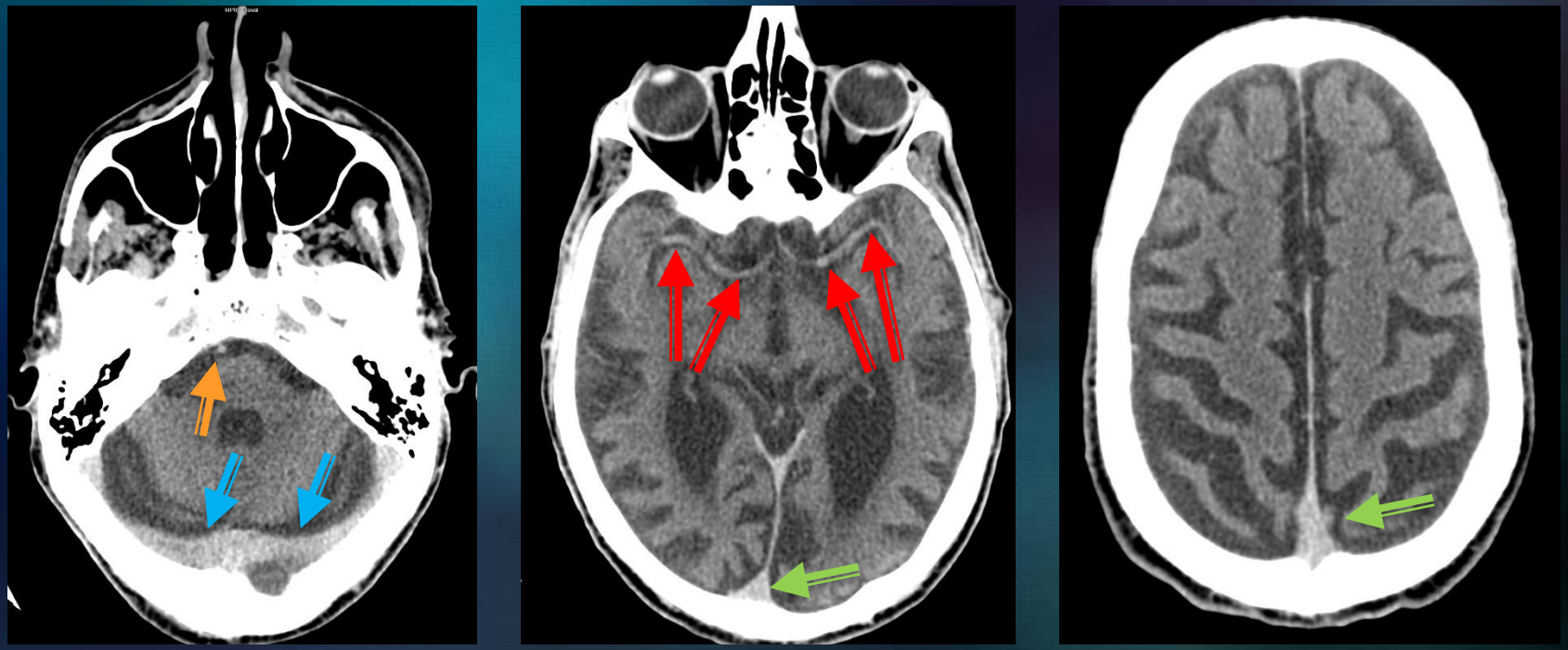

Non-contrasted, axial CT images show diffusely hyperdense vessels including the **basilar artery**, **MCA's**, **transverse sinuses** and **superior sagittal sinus**. This is caused by retained contrast that was given to this patient with end stage renal disease without a focal neurologic deficit for an abdominal CT 4 hours prior to the head CT study.

Multiple Hyperdense Vessel Mimic

- Hyperosmolarity secondary to inebriation

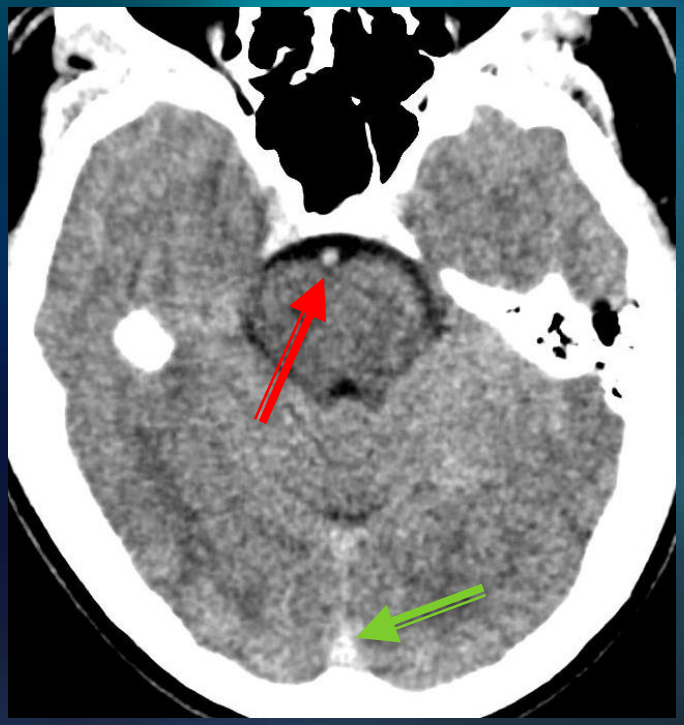

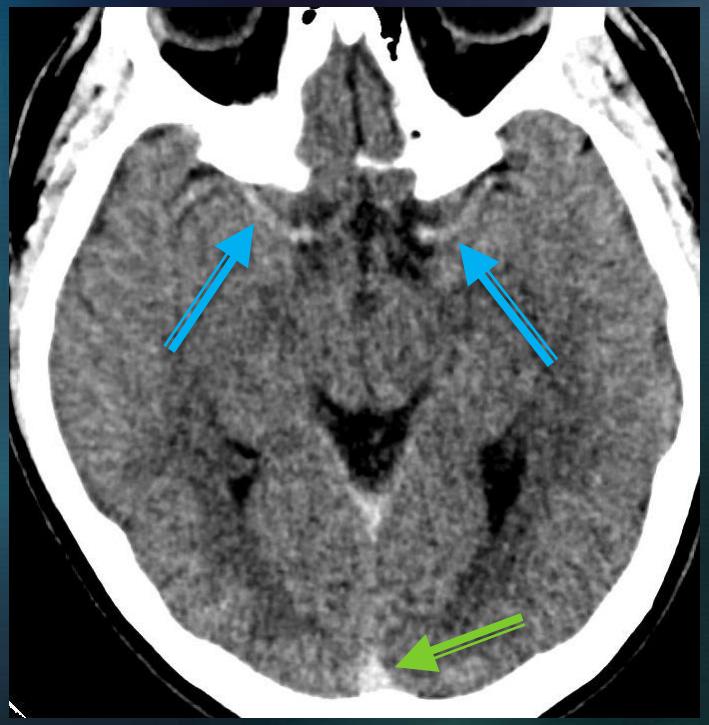

Non-contrasted, axial CT images reveal a **hyperdense basilar artery** similar to the SIM case presented earlier. In this patient, however, there is also **hyperdensity of the MCA bilaterally** and **superior sagittal sinus**. The diffuse nature of the vascular hyperdensity should trigger the correct diagnosis of elevated serum osmolality in this patient with alcohol intoxication.

Multiple Hyperdense Vessel Mimic

- Hypoxic Brain Injury

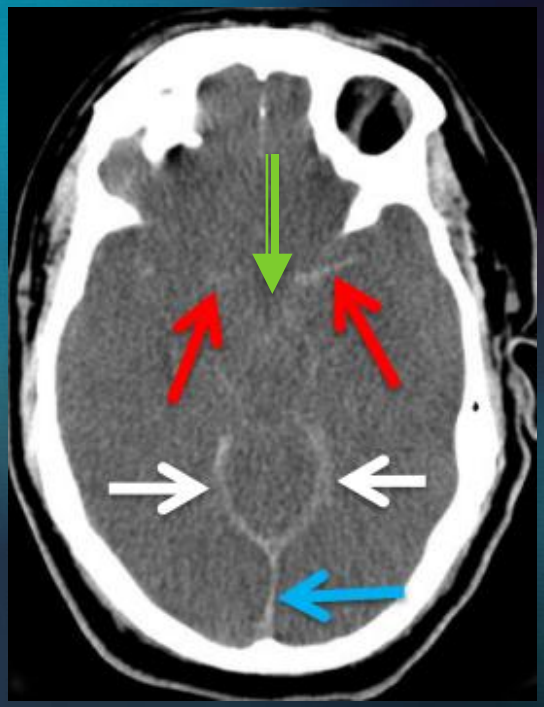

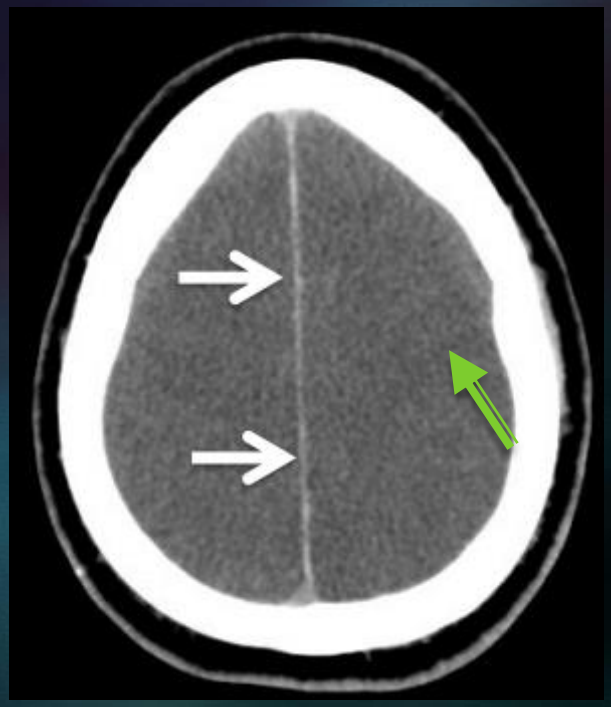

Non-contrasted CT shows diffuse hyperdense **arterial** & **venous** vessels. As in the prior two cases, this might be related to retained contrast or elevated hematocrit. In this patient however, this is caused by diffuse edema manifesting as **loss of grey white differentiation & effacement of the sulci** due to hypoxic brain injury. The hyperdense **tentorium & falx** provides an easily detectable hint to the correct diagnosis.

Multiple Hyperdense Vessel Mimic

- Polycythemia Vera

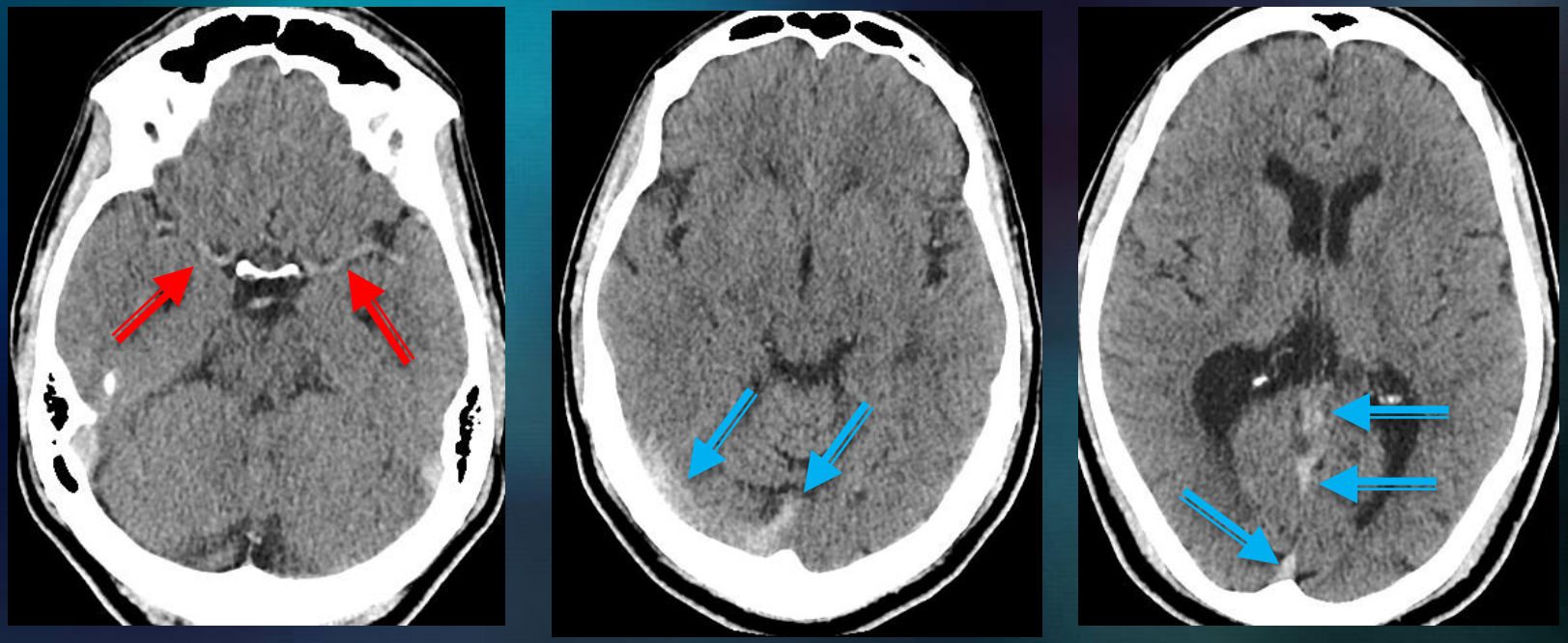

Non-contrasted CT shows diffuse hyperdense **arterial** & **venous** vessels. In this patient however, this is caused by pathologically elevated hematocrit due to polycythemia vera mimicking “red thrombus” (acute thrombus). Of note, polycythemia vera patients are more prone to infarction(s). Therefore, careful attention must be paid to clinical history & secondary signs of infarctions in each of these patients.

Conclusion

- Hyperdense vessel sign = commonly missed finding
- Radiologists can minimize their risk of missing the hyperdense vessel sign by:
  - ✓ Specifically noting the density of arteries and veins
  - ✓ Observing whether it is diffuse or focal
  - ✓ Investigating the clinical history
    - Neurologic deficits
    - Comorbid conditions (ie ESRD, Polycythemia vera, dehydration)
    - History of recent contrast administration
- If a hyperdense vessel sign is suspected, this requires a phone call to the ordering physician.

References

- Liebeskind DS1, Sanossian N, Yong WH, Starkman S, Tsang MP, Moya AL, Zheng DD, Abolian AM, Kim D, Ali LK, Shah SH, Towfighi A, Ovbiagele B, Kidwell CS, Tateshima S, Jahan R, Duckwiler GR, Viñuela F, Salamon N, Villablanca JP, Vinters HV, Marder VJ, Saver JL. CT and MRI early vessel signs reflect clot composition in acute stroke. Stroke. 2011 May;42(5):1237-43. doi: 10.1161/STROKEAHA.110.605576. Epub 2011 Mar 10.
- New PF, Aronow S. Attenuation measurements of whole blood and blood fractions in computed tomography. Radiology. 1976 Dec;121(3 Pt. 1):635-40.
- Kirchhof K, Welzel T, Mecke C, Zoubaa S, Sartor K. Differentiation of white, mixed, and red thrombi: value of CT in estimation of the prognosis of thrombolysis phantom study. Radiology. 2003 Jul;228(1):126-30. Epub 2003 May 1.
- Haridy J, Churilov L, Mitchell P, Dowling R, Yan B. Is there association between hyperdense middle cerebral artery sign on CT scan and time from stroke onset within the first 24-hours?. BMC Neurol. 2015 Jul 3;15:101. doi: 10.1186/s12883-015-0358-5.